



# INTRAPLEURAL INSTILLATION OF THE TRIFUNCTIONAL ANTIBODY CATUMAXOMAB FOR OUTPATIENT THERAPY OF MALIGNANT PLEURAL EFFUSIONS RELATED TO METASTATIC BREAST AND OVARIAN CANCER

CHRISTIAN M. KURBACHER<sup>1,3</sup>, CLAUDIA SCHWEITZER<sup>1</sup>, GABRIELE KOLBERG<sup>1</sup>,  
SUSANNE HERZ<sup>1</sup>, OLYMPIA HORN<sup>1</sup>, SANDRA SPERLING<sup>1</sup>, A. TABEA KURBACHER<sup>1</sup>, JUTTA A. KURBACHER<sup>2</sup>

<sup>1</sup>Division of Gynecologic Oncology and <sup>2</sup>Division of General Gynecology and Obstetrics, Gynecologic Center Bonn-Friedensplatz, Bonn,Germany; <sup>3</sup>Faculty of Medicine, University of Cologne, Cologne, Germany

### BACKGROUND

Pleural effusion (PE) is a frequent complication of various malignancies with metastatic spread to the pleural cavity. Malignancies most frequently associated with PE are carcinomas of the lung, breast, ovary, and malignant mesothelioma. Major symptoms associated with PE are dyspnea, asthenia, fatigue, and pain. Standard of care in the treatment of PE comprises serial punctures, insertion of a permanent pleural drain, and pleurodesis with sclerosants like talc, or silver nitrate. Although low toxic in general, chemical pleurodesis requires hospitalization and admission of the patients (pts) to an intensive-care unit. This is due to the fact that complete evacuation of the pleural cavity by using a vacuum drainage system is mandatory prior to the installation of a sclerosant. Intrapleural (IPL) instillation of sclerosant cytostatics or antibiotics such as bleomycin, mitomycin C, mitoxantrone, tetracycline or doxycycline can be performed more easily in outpatients but may be also less effective in regard to the puncture-free interval (PuFI).

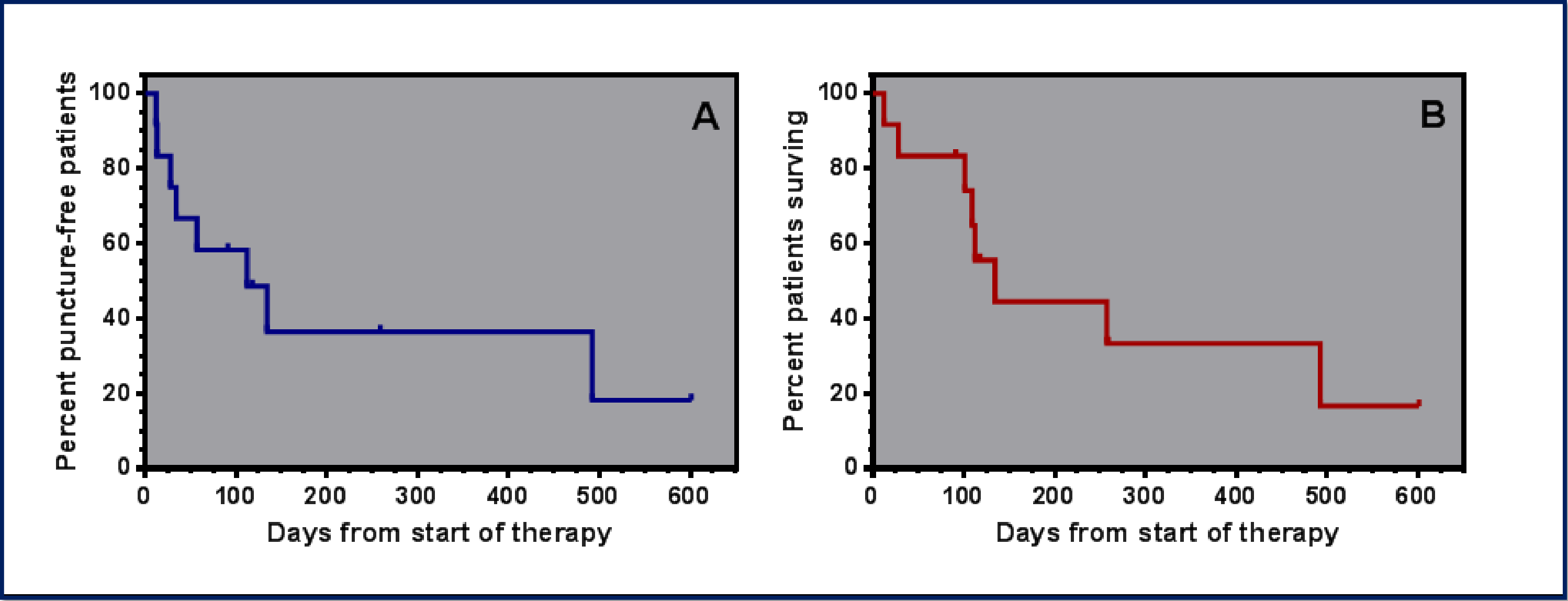
Epithelial tumors producing malignant effusions often express the epithelial cell adhesion molecule (EpCAM). Catumaxomab is a trifunctional monoclonal antibody (anti-EpCAM x anti-CD3) approved in 2009 for the intraperitoneal treatment of malignant ascites related to EpCAM-positive epithelial neoplasms. Catumaxomab has been found to be active in the treatment of malignant ascites in several phase II-IV studies [Heiss et al., 2010, Kurbacher et al., 2013, Sehoul et al., 2014]. Predominant side effects were fever, abdominal pain, and nausea/vomiting. One of the most intriguing findings of CARMA, a large multicenter phase IV trial performed in a clinical routine setting was the fact, that outpatient treatment was possible in 27% of the pts [Kurbacher et al., 2013]. Intraperitoneal catumaxomab therapy normally requires 4 subsequent instillations at increasing dosages (i.e. 10, 20, 50, and 150 µg absolute dose) over a 14 days period. For IPL treatment, serial instillations mostly appear to be inappropriate apart from a very few pts who have a permanent pleura catheter inserted. Successful immunotherapy requires the application of an antibody at its saturation level which for catumaxomab may be reached at 50, or even 20 µg. We hereby report on a series of intensively pretreated outpatients suffering from PE related to metastatic breast (MBC) or recurrent epithelial ovarian cancer (ROC) treated with IPL catumaxomab in a routine clinical setting.

### METHODS

A total of 12 pts with PE (MBC n=7, ROC n=5) were treated with IPL catumaxomab. Six MBC pts had invasive-lobular carcinoma, the remainder had estrogen receptor-negative, HER2-positive invasive-ductal adenocarcinoma. All five ROC pts suffered from high-grade papillary serous adenocarcinoma (type II ovarian carcinoma). EpCAM-positivity was confirmed by immunohistochemistry in all cases. All pts were heavily pretreated having failed a median of 6 (3-12 ) prior systemic treatments. Baseline characteristics of the pts are summarized in Table 1. In 10 pts, ultrasound-guided pleural puncture was performed in an outpatient setting. In these pts, catumaxomab was given at an absolute dose of 50 µg administered as a 10 min IPL injection. In one pt, this procedure was repeated after 25 days. One pt was referred to our institution for further treatment after implantation of a permanent IPL catheter. In this instance, catumaxomab treatment was given according to the intraperitoneal scheme at 4 increasing doses (i. e. 10, 20, 50, 150 µg) instilled over 3 hours for a 14 days treatment period. Standard premedication included IV administration of metamizole (1 g) and granisetron (3 mg). After, IPL instillation, the analgesic/antipyretic and antiemetic treatments were continued for 3 consecutive days by using oral or subcutaneous formulations of the particular drugs. In one pt experiencing hypotension during IV metamizole, antipyretic treatment was changed to 1 g of paracetamol. In patient #10 with known severe allergy towards all kinds of established non-steroidal pain-killers, we abstained from administering antipyretics. In this particular case, analgesic premedication consisted of IV pethidine at 50 µg. Adverse effects were recorded according to the CTCAE 4.03 scale. The PuFI was defined as the interval between the start of IPL catumaxomab and first subsequent pleural puncture due to symptomatic PE. OS was calculated from the start of catumaxomab and death of any reason or loss to follow-up. The puncture-free survival was calculated from start of IPL catumaxomab and next puncture, death or loss to follow-up, whatever was the first to occur.

### RESULTS

Treatment results are summarized in Table 2. Outpatient IPL catumaxomab was generally well tolerated. As with intraperitoneal instillation, major side effects can be considered cytokine-related and comprised fever, pain, hypotension, and dyspnea. Side effects were well controlled by routinely administered supportive medication including both antipyretics and antiemetics and never exceeded CTCAE grade II with the exception of one case in which the administration of non-steroidals had to be avoided (patient #10). This patient was also the only one needing hospitalization secondary to IPL due to fever and local pain. Only 3 pts developed symptomatic PE after IPL catumaxomab treatment and needed subsequent punctures. All but 4 pts were able to undergo subsequent antineoplastic treatment following IPL catumaxomab. Recently 4 pts are still alive. Median PuFS is 112 days and median OS is 134 days (Figure 1).



**Figure 1:** Survival after intrapleural catumaxomab treatment.  
A, puncture-free survival after start of intrapleural catumaxomab (median: 112 days)  
B, overall survival after start of intrapleural catumaxomab (median: 134 days)

Table 1: Patients´ characteristics						
Patient No.	Age (yrs)	Year of Diagnosis	Tumor Type	Histology	No of preceding systemic treatments	Karnofsky Performance Status (%)
1	67	2005	Breast	invasive lobular (ER+, HER2 -)	3	70
2	60	2000	Breast	invasive ductal (ER-, HER2 +)	7	70
3	69	2004	Breast	invasive lobular (ER+, HER2 -)	5	70
4	33	2004	Ovary	papillary-serous	12	70
5	43	2008	Ovary	papillary-serous	7	70
6	64	2006	Breast	invasive lobular (ER+, HER 2+)	5	60
7	62	2006	Breast	invasive lobular (ER+, HER2 -)	6	60
8	46	2007	Ovary	papillary-serous	11	60
9	49	2007	Breast	invasive lobular (ER+, HER2 -)	6	90
10	41	2005	Ovary	papillary-serous	3	80
11	72	2006	Breast	invasive lobular (ER+, HER2 -)	3	70
12	75	2004	Ovary	papillary-serous	9	70

Table 2: Results of intrapleural catumaxomab therapy						
Patient No.	CATU dose (µg)	No. CATU applications	Relevant side effects	Subsequent IPL punctures	PuFI (days)	OS (days)
1	50	1	-	-	601+	601+
2	50	1	dyspnea, hypotension	1	13	257
3	10, 20, 50, 150	4	-	-	112	112
4	50	1	-	-	492	492
5	50, 50	2	fatigue	1	34	109
6	50	1	-	-	91+	91+
7	50	1	-	-	28	28
8	50	1	pain	-	134	134
9	50	1	fever, pain, dyspnea	-	259+	259+
10	50	1	fever, pain, fatigue	1	57	101
11	50	1	-	-	118+	118+
12	50	1	-	-	12	12

### CONCLUSIONS

- Outpatient IPL catumaxomab feasible in this intensively pretreated group of patients with either MBC or ROC.
- IPL catumaxomab was generally well tolerated. Relevant side effects were recorded in only 5 patients and rarely exceeded CTCAE grade II.
- The quality of adverse effects were similar to that seen with intraperitoneal catumaxomab therapy for malignant ascites.
- Toxicity was manageable even in relatively “frail” patients with a low initial performance status.
- IPL catumaxomab, although given as a 50 µg single shot in most patients, could effectively control symptomatic PE.
- Eight out of twelve patients (66.7%), were able to undergo a subsequent systemic antineoplastic treatment.
- A median PuFS of 112 days and a median OS 134 demonstrated a clinically meaningful activity of IPL catumaxomab.
- IPL catumaxomab offers a new, low-toxic and easy-to-administer option in patients with symptomatic PE related to MBC or ROC which, in contrast to pleurodesis with talc or silver nitrate, can be given in an outpatient setting in the vast majority of patients.